Veterinary Research Communications (2026) 50:79
https://doi.org/10.1007/s11259-025-11019-w

RESEARCH

Protective effects of dietary *Cucurbita pepo* on oxidative damage, histopathological alterations, and endoplasmic reticulum stress in the brain and gills of *Oreochromis niloticus* exposed to trace elements

Afaf N. Abdel Rahman[1] · Mohammed S. Sobh[2] · Abdallah Tageldein Mansour[3] · Ahmed S. AlSaqufi[3] · Yousef Alkhamis[3] · Hesham A. Hassanien[3] · Ahmed Abbas[3] · Tarek Khamis[4] · Rowida E. Ibrahim[1] · Sara T. Elazab[5]

Received: 17 October 2025 / Accepted: 28 November 2025
© The Author(s), under exclusive licence to Springer Nature B.V. 2025

Abstract

Waterborne trace elements (TE), such as mercury (Hg) and zinc (Zn), are environmental contaminants that often co-occur in aquatic ecosystems. *Cucurbita pepo* (pumpkin peel; PP) is a medicinal plant with diverse pharmacological properties. Accordingly, this innovative trial looked at the efficacy of PP, administered as powder (12.00 g/kg diet), in mitigating the toxicological effects of a mixture of trace elements (MTE) containing Hg (0.05 mg/L) and Zn (7.00 mg/L) in *Oreochromis niloticus*. A total of 160 fingerlings (28.50 ± 1.33 g) were randomly assigned to four groups, with four replicates per group: control, PP, MTE, and PP + MTE. The experiment was conducted over two months. The findings disclosed a reduced fish survival rate (72.50%) and a pronounced neuro-stress response following MTE exposure, as indicated by elevated cortisol, norepinephrine, and glucose concentrations, along with decreased acetylcholinesterase activity. The MTE exposure also induced oxidative stress in gills, evidenced by increased malondialdehyde concentration and diminished glutathione peroxidase activity, and reduced glutathione content. Additionally, MTE caused extensive histopathological alterations in both brain and gill tissues. Furthermore, MTE exposure induced endoplasmic reticulum stress and activated apoptotic pathways, as evidenced by the significant upregulation of cysteine–aspartic acid protease-3 (*casp-3*), eukaryotic translation initiation factor 2 A (*eif-2a*), C/EBP homologous protein (*chop*), and X-box binding protein 1(*xbp-1*) and inositol-requiring enzyme 1 alpha (*ire-1α*), activating transcription factor 6 (*atf-6*), and glucose-regulated protein 78 (*grp-78*) genes in both the brain and gills. Remarkably, dietary supplementation with PP improved these parameters and restored normal tissue histology. These findings suggest that PP can be effectively incorporated into the diet of *O. niloticus* to mitigate the toxic effects of MTE exposure.

Keywords ER stress · Fish physiology · Genotoxicity · Trace elements · Pumpkin peel · Oreochromis niloticus

✉ Afaf N. Abdel Rahman
afne56@gmail.com

✉ Abdallah Tageldein Mansour
amansour@kfu.edu.sa

[1] Department of Aquatic Animal Medicine, Faculty of Veterinary Medicine, Zagazig University, PO Box 44511, Zagazig, Egypt

[2] Department of Pathology, Faculty of Veterinary Medicine, Zagazig University, PO Box 44511, Zagazig, Egypt

[3] Department of Aquaculture and Animal Production, College of Agricultural and Food Sciences, King Faisal University, PO Box 420, Hofuf, Al- Hasa 31982, Saudi Arabia

[4] Department of Pharmacology, Faculty of Veterinary Medicine, Zagazig University, PO Box 44511, Zagazig, Egypt

[5] Department of Pharmacology, Faculty of Veterinary Medicine, Mansoura University, Mansoura 35516, Egypt

Published online: 23 December 2025

Introduction

Ecological pollution is one of the foremost issues threatening aquaculture productivity and sustainability, as well as posing a great concern for public health (Naidu et al. 2021; Abdel Rahman et al. 2023; Fred-Ahmadu et al. 2024). Trace elements (TE) are commonly recognized as significant pollutants in aquatic habitats (Shaalan 2024). Once released into waterways, TE disintegrates in water and readily build up in fish tissues, potentially resulting in adverse physiological effects and posing risks to consumers (Ray and Vashishth 2024). Some TE, like mercury (Hg), cadmium (Cd), and lead (Pb), are toxic, whereas others, including zinc (Zn), iron (Fe), and copper (Cu), are necessary for life in trace amounts (Ciosek et al. 2023).

Hg is one of the major TE that can cause serious harm to aquatic organisms, even at low levels, because of its non-biodegradable nature (Bella et al. 2021). In aquatic environments, Hg is primarily introduced through agricultural runoff containing pesticide residues (Azevedo et al. 2019). Three forms of Hg are prevalent in the environment: inorganic (mercury chloride, $HgCl_2$), organic (methylmercury, CH_3Hg^+), and elemental (Hg^0). Among these, mercury chloride is a particularly toxic form, as it can cross biological barriers and interact with amino acids to form organomercury complexes, leading to apoptosis and DNA damage (Caglayan et al. 2019; Kim et al. 2021).

In addition, Zn is a physiologically vital TE that plays a crucial role in animal growth and serves as a cofactor for numerous enzymes involved in protein, lipid, and nucleic acid metabolism (Hogstrand 2011). Although ZN is an essential micronutrient, exposure to elevated waterborne concentrations originating from pesticides, industrial discharges, and pharmaceutical wastes can be harmful to aquatic species (Bowen et al. 2006; Zheng et al. 2011). These hazards are exacerbated by its near-persistent presence in the environment, owing to its ability to undergo biotransformation between various oxidation phases or organic complexes (Kwon et al. 2022). Zn can also penetrate fish gills and accumulate within the mucus layer, causing irreparable damage to the gill epithelium and ultimately leading to suffocation (Papagiannis et al. 2004; Kim et al. 2019).

Several environmental surveys have reported the presence of multiple TE in polluted aquatic ecosystems, including Hg and Zn, underscoring their potential ecological and health hazards. For instance, Hg and Zn concentrations were recorded at 0.01 and 0.48 mg/L, respectively, in the Halda River, Chittagong, Bangladesh (Bhuyan and Bakar 2017), while the levels of 0.046 and 0.098 mg/L were observed in the Wen-Rui Tang River in China (Qu et al. 2018). In Egypt, Hg and Zn levels of 0.153 and 1.04 mg/L, respectively, were detected in the El-Rayah El-Tawfeeky canal (Shaalan 2024).

Worldwide, Nile tilapia (*Oreochromis niloticus*) is one of the most widely farmed fish species due to its high consumer demand, ease of culture, and favorable behavioral and physiological characteristics, which also make it an excellent model for understanding the detrimental impacts of pollution in aquatic habitats (Mahi et al. 2022; El-Sayed and Fitzsimmons 2023). Exposure to TE can cause multiple adverse effects, including biochemical and physiological disruptions in fish (Abdel-Tawwab et al. 2016; Wang et al. 2024). Cortisol (COR), nor-epinephrine (NOR), and glucose (GLU) serve as key physiological indicators of stress following TE toxicity, validating the activation of stress response pathways (Adam et al. 2023; Yuan et al. 2025).

Furthermore, TE exposure generates reactive oxygen species (ROS), which can exceed the capacity of antioxidant systems to neutralize them, thereby promoting lipid peroxidation (Khalil et al. 2017). Antioxidant components such as glutathione peroxidase (GPx) and reduced glutathione (GSH) play key roles in mitigating oxidative damage; however, their activities are often disrupted under TE exposure (Alkaladi 2019; Waheed et al. 2020). The accumulation of ROS caused by TE toxicity in fish tissues, particularly in the gills and brain, leads to cellular damage and histopathological alterations (Srivastava and Prakash 2019; Reda et al. 2025). This oxidative injury can result in synaptic degeneration and neurotransmitter malfunction, ultimately contributing to neurotoxicity, behavioral abnormalities, and mortality in fish (Zhu et al. 2016; Nofal et al. 2019). Acetylcholinesterase (AchE) is a crucial neurobiochemical indicator used to assess TE toxicity (Yuan et al. 2025). Moreover, the endoplasmic reticulum (ER) is a fundamental organelle accountable for protein synthesis, proper folding, and the degradation of cellular contaminants (Almanza et al. 2019). When the ER function is disrupted by environmental stressors such as TE exposure, the accumulation of misfolded or unfolded proteins induces ER stress. This condition activates the unfolded protein response (UPR) and may subsequently trigger apoptosis (Rana 2020; Demircan et al. 2024).

Consequently, these considerations highlight the need to investigate the combined effects of Hg and Zn in aquatic species, particularly *O. niloticus*. Furthermore, it is crucial to identify eco-friendly, cost-effective, safe, and efficient strategies to mitigate the damaging implications of TE and ensure sustainable fish production in healthy aquatic environments (Hama Aziz et al. 2023). The use of dietary additives with natural antioxidant properties, especially those derived from medicinal plants, has recently emerged as a promising approach to reduce stress and improve the fish's immunity (Ibrahim et al. 2023; Karataş 2024; Sánchez-Velázquez et al. 2024). These supplements can alleviate Hg and Zn toxicity through several mechanisms, including

the formation of insoluble complexes or metal-binding ligands that decrease metal bioavailability, thereby reducing uptake and toxicity. In addition, their antioxidant and anti-inflammatory properties further contribute to mitigating TE-induced damage (Karamać 2009; Mellingen et al. 2022).

Cucurbita pepo (pumpkins), a member of the *Cucurbitaceae* family, is widely utilized in both food and traditional medicines (Gohari et al. 2011). Various parts of the plant, including the fruits, flowers, peel, leaves, and seeds, are edible and possess nutritional value (Kim et al. 2012). Its long history of use is supported by numerous pharmacological studies demonstrating antimicrobial, antiulcer, anti-inflammatory, anticancer, and antioxidant features (Chen et al. 2012; Noumedem et al. 2013; Akubugwo et al. 2022). These beneficial effects are primarily attributed to its rich content of bioactive phytocompounds such as alkaloids, oleic acids, flavonoids, and palmitic acids (Ratnam et al. 2017). In *O. niloticus*, dietary pumpkin peel (PP) has shown immune-stimulating, growth-promoting, and antioxidant potentials (Ibrahim et al. 2025b). However, its neuroprotective and anti-stress effects against TE-induced toxicity in fish remain largely unexplored.

Research to date suggests that a single exposure to Hg or Zn can impair the biological functions of *O. niloticus*. However, the impact of their co-exposure on the neurological and branchial functions remains poorly understood. This study, therefore, aimed to evaluate whether dietary PP can alleviate ER stress, apoptosis, oxidative stress, and histopathological alterations in the brain and gills of *O. niloticus* subjected to long-term exposure to a water-borne mixture of TE (MTE).

Table 1 Constituents and chemical analysis of the basal diet (% dry matter basis)

Ingredients	%
Corn gluten 60% CP	11.00
Fish meal	18.00
Fish oil	6.00
Ground yellow corn	24.30
Premix[#]	1.20
Soybean meal 44%	25.50
Wheat	5.00
Wheat bran	9.00
Chemical analysis	
Nitrogen-free extract	42.56
Fat	9.98
Crude fiber	3.82
Ash	6.46
Crude protein	37.18

[#]Premix/kg contains: choline (110,000 mg), selenium (44 mg), zinc (6.6 g), iron (6.6 g), biotin (6.6 mg), copper (330 mg), manganese (1320 mg), iodine (110 mg), vitamin E (11,000 mg), vitamin D (110,000 IU), vitamin C (50 g), vitamin B_2 (660 mg), vitamin A (550,000 IU), vitamin B_6 (1045 mg), vitamin B_5 (1100 mg), vitamin B_1 (440 mg), vitamin B_9 (55 mg), vitamin B_3 (13,200 mg), and vitamin K (484 mg)

Materials and methods

MTE preparation and tested diet formulation

All glassware utilized in this study was cleaned sequentially with a local commercial detergent for 24 h, 10% nitric acid (HNO_3; Merck, Germany), and distilled water (El-Sappah et al., 2022). Mercury chloride and zinc sulfate heptahydrate ($ZnSO_4 \cdot 7H_2O$) from Merck (Germany) were used as sources of Hg and Zn. For this trial, Hg and Zn concentrations were 0.05 and 7.00 mg/L, respectively, representing 1/10 of the 96-h median lethal concentrations (LC_{50}) of 0.50 mg/L for Hg and 70.00 mg/L for Zn (Abdel-Tawwab et al. 2004, 2011). These concentrations reflect environmentally relevant levels as reported by Qu et al. (2018) and Abdel-Baky et al. (1998). Separate stock solutions (1000 mg/L) of mercury chloride and zinc sulfate were prepared in deionized water and diluted to the target concentrations immediately before use.

Pumpkin fruits were obtained from the local market in Zagazig, Egypt. The fruits were thoroughly rinsed with distilled water, then soaked in 2% acetic acid for 15 min to remove contaminants. They were rinsed again with distilled water and drained using paper towels. The PP was cut into small pieces (2–3 mm) with a sterilized stainless-steel knife and dried in a hot-air oven at 60 °C (Saewan and George 2020). After drying, the PP was finely ground using an electric mixer and incorporated into the feed at 0 g/kg (control diet) or 12 g/kg (PP diet). The chemical composition of PP comprised total phenolics (0.26%), total flavonoids (2.72%), total alkaloids (0.61%), total terpenoids (1.57%), and minerals (14.00%), as reported in our previous study (Ibrahim et al. 2025b). Following NRC (2011) guidelines, dietary formulations were designed to meet the nutritional requirements of *O. niloticus*. The basal diet was chemically analyzed (AOAC 2005), and with results were presented in Table 1. Feed ingredients were mechanically mixed, pelletized (1.5 mm diameter), air-dried at 25 °C for 24 h, and stored at 4 °C until use.

Fish rearing and experimental protocol

The study protocol was approved by the Zagazig University Authority for Animal Use in Research (approval no. ZU-IACUC-2-F-4-2024). Mixed-sex *O. niloticus* fingerlings (10 weeks old; average weight 28.50 ± 1.33 g) were obtained from a private fish farm in Kafr ELSheikh Governorate,

Egypt. Ten fish were randomly assigned to each glass tank (80 × 70 × 35 cm) containing 100 L of dechlorinated water. Tanks were equipped with air stones and a central air compressor to ensure continuous aeration. During a 15-day acclimation period, fish were fed a basal diet three times daily (09:00, 13:00, and 17:00) to apparent satiation and maintained under a 12-h light/12-h dark photoperiod. After acclimatization, 160 fish were randomly divided into four treatments with four replicates each (10 fish per replicate) for two months: control, PP, MTE, and PP + MTE. The control and PP groups received control and PP diets without MTE exposure. While the MTE and PP + MTE groups were given control and PP diets, along with exposure to the MTE solution. Fish were fed to apparent satiation three times daily (09:00, 13:00, and 17:00 h). Tank water was completely renewed twice weekly, and MTE solutions were replenished to maintain the target concentrations after each renewal.

During the two-month exposure period, fish mortalities were recorded. Water quality was monitored throughout the study (APHA 2005) and maintained within acceptable limits, with the following parameters: ammonia, 0.01 ± 0.001 mg/L; dissolved oxygen, 6.80 ± 0.29 mg/L; nitrite, 0.03 ± 0.004 mg/L; temperature, 24.65 ± 2.00 °C; pH, 6.90 ± 0.88; total dissolved solids, 225.00 ± 1.50 mg/L; total hardness, 140.00 ± 1.50 mg/L; conductivity, 367.00 ± 1.70 µS/cm; magnesium (Mg^{+2}), 18.00 ± 0.23 mg/L; calcium, 32.00 ± 0.15 mg/L; chloride (Cl^{-}), 16.50 ± 0.50 mg/L; sulfate (SO_4^{2-}); 51.00 ± 1.20 mg/L; and bicarbonate (HCO_3^{-}) 95.50 ± 2.50 mg/L.

Sampling

At the end of the two-month trial, two fish were randomly chosen for blood collection from each replicate (8 fish/group). The fish were sedated with a 100 mg/L benzocaine solution following a prior procedure (Neiffer and Stamper 2009). Using plastic syringes (1 mL) free of anticoagulants, pooled blood samples were obtained from the fish and allowed to coagulate at 4 °C. To gather the serum, samples were spun in a centrifuge for 10 min at 1198 ×g and were subsequently used for stress- and neuro-related assays.

Following the blood sampling, the same fish were euthanized using a 300 mg/L benzocaine solution (AVMA 2007) to obtain the brain and gill tissues for gene expression assays. The remaining fish were killed in the same manner and the gills from eight fish per group were taken for oxidant/antioxidant analysis. Additionally, brain and gill tissue specimens from an additional eight fish in each group were collected for histopathological evaluation.

Stress and neuro-linked assays

Serum samples were used to measure the concentrations of COR, NOR, and GLU, and AchE activity. Using a Fish Cortisol ELISA kit of CUSABIO, USA (Catalog No. CSB-E08487f), serum COR concentration was measured (Tahir et al. 2018). In brief, duplicates of the cortisol antibody-containing sample were added to each well that had been pre-coated with an antigen. At 37 °C, the plate was then incubated for 40 min. Horseradish peroxidase (HRP) conjugate was added to the wells after they had been cleaned three times to get rid of unbound antibodies. The plate was then incubated for 30 min at 37 °C. Following another washing, the plate was incubated (20 min/37°C) with tetramethylbenzidine substrate, which was added for HRP activity detection. With a gentle shake, a stop solution was added and thoroughly mixed. The optical density was measured at 450 nm to estimate the cortisol levels.

Lee et al. (2021) methodology was followed to assess serum NOR, implementing an HPLC system. A Shimadzu LC-10 A HPLC system with a fluorescence detector (Shimadzu, Kyoto, Japan) and a column ODP-50G Asahipak (Showa Denko, Tokyo, Japan) was used for the HPLC analysis. NOR was derivatized at 39 °C, and the resulting fluorescent derivative was detected at 350 nm.

GLU concentration (Cat No.: GL 1320) was evaluated spectrophotometrically using commercial kits (Biodiagnostics Co., Cairo, Egypt) in line with Trinder (1969) strategy. When GLU was converted to gluconic acid by the GLU oxidase enzyme, hydrogen peroxide (H_2O_2; Merck, Germany) was produced. A specific shade of pink was then produced by the reaction of hydrogen peroxide with the chromogenic oxygen acceptor phenol-aminophenazone in the presence of GLU peroxidase. The GLU quantity is identified by the magnitude of the color that is formed. Furthermore, the activity of AchE was evaluated by applying commercial ELISA kits (Catalog No: MBS035436) provided by MyBioSource in San Diego, USA, and measured at 450 nm.

Oxidant/antioxidant assays

Markers of oxidative damage, including malondialdehyde (MDA), and antioxidant status, comprising GPx activity and GSH concentration, were estimated in gill tissues. Prior to homogenization in phosphate buffer saline (pH = 7.5), gill tissues were rinsed three times in a 0.90% sodium chloride solution. The homogenates were then centrifuged at 1198 × g for 15 min, and the resulting supernatants were collected in sterile tubes for subsequent assays.

Kits of the Biodiagnostics Co. (Cairo, Egypt; Cat. No. MD 2529, GP 2524, and GR 2511) were employed to identify MDA, GPx, and GSH, respectively. Following the

protocol of Ohkawa et al. (1979), the MDA concentration was established by employing the thiobarbituric acid procedure. This assay is based on the reaction of MDA with thiobarbituric acid (95 °C/30 min) in an acidic solution, generating a colored final product (pink thiobarbituric acid reactive component). This product's absorbance was estimated at 534 nm.

At an absorbance rate of 340 nm, GPx activity was evaluated colorimetrically using a prior technique (Paglia and Valentine 1967). In the presence of glutathione reductase, organic peroxide can be transformed into an oxidized glutathione by the GPx enzyme, which is subsequently recycled to its reduced state. Using the method of Beutler et al. (1963), GSH levels were determined colorimetrically. This assay is based on the reaction of GSH with 5,5′-dithiobis-(2-nitrobenzoic acid) (DTNB) to form 5-mercapto-2-nitrobenzoic acid (a persistent yellow-colored molecule). The absorbance of the reaction mixture was determined within 30 min of the color generation at 412 nm.

Histopathological assessment

Samples of the brain and gill tissues (8 fish/group) were gathered and prepared using standard histological techniques (Suvarna et al. 2018). Tissues were rapidly fixed in 10% neutral buffered formalin for 24 h at room temperature, dried in ethyl alcohol (in ascending grades; 70–100%), and cleared in xylene and enclosed in paraffin wax. Following that, paraffin sections were cut into thick slices (5 µm) using a microtome (Leica RM2125, England) and stained with hematoxylin and eosin. The slides were examined under a microscope (AmScope; Irvine, CA, USA).

RNA recovery and transcription of genes linked with ER-stress pathways

Following a two-month trial, RNA was isolated from brain and gill tissue samples (50 mg), implementing QIAzol of Qiagen (Germany) as directed by the supplier. At 260/280 nm, the extracted RNA was analyzed, and its purity was verified with a Thermo Scientific NanoDrop® spectrophotometer (ND-1000 UV-Vis; Waltham, USA). An Applied Biosystems reverse transcriptase kit (California, USA) was applied to create the complementary DNA, and 500 ng of the total RNA was reverse-transcribed per the manufacturer's guidelines. Gene expression associated with ER-stress mechanisms was evaluated in brain tissues [cysteine–aspartic acid protease-3 (*casp-3*), eukaryotic translation initiation factor 2 A (*eif-2a*), C/EBP homologous protein (*chop*), and X-box binding protein 1 (*xbp-1*)] and gill tissues [inositol-requiring enzyme 1 alpha (*ire-1α*), activating transcription factor 6 (*atf-6*), and glucose-regulated protein78 (*grp-78*)] was evaluated. The primers used for these genes, obtained from Sangon Biotech (Beijing, China), are listed in Table 2.

According to an earlier procedure (Abdel Rahman et al. 2025), quantitative polymerase chain reaction (qRT-PCR) was performed using the Rotor-Gene Q 2 plex real-time heat cycler (Qiagen, Germany). The qRT-PCR cycle conditions involved an initial denaturation (95 °C/10 min), followed by 40 PCR [denaturation (95 °C/10s), annealing (60 °C/15 s), and extension (72 °C/15 s)]. Before analysis, housekeeping genes [elongation factor 1-alpha (*ef-1α*)], beta-actin (*β-actin*), and ubiquitin-conjugating enzyme 2 (*ube2*) underwent stability testing. *β-actin* was chosen as the reference gene for brain samples, while the *ef-1α* was selected

Table 2 List of primers for qRT-PCR amplification

Target gene	Primer sequence	Accession number	Melting temperature	Size	Primer efficiency
casp-3	TTCTTTGGTACGGACGGCTC CCTCTGCAAGCCTGGATGAA	NM_001282894.1	60.04 60.03	116	99.35
eif-2a	TTCGACTCCATCGCCAACAA GGTACTGATACAGGCGGACG	XM_005462748.4	59.97 59.97	139	96.54
chop	GACACAGGAGGGGCAAAACT GCTCCTTCTGGAAGCACAAA	XM_013275519.3	60.18 58.39	81	98.5
xbp-1	GGTGGAGGAGGAGACCATCT ATGTCGCTGAAAGGGGAAGG	XM_013276886.2	60.03 60.04	198	95.45
ire-1α	AAGCAGGAAGGAAACGCTGA CTTGCCCTCCCAGTCACATT	XM_025905478.1	59.89 59.96	197	97.5
atf-6	TGGTATGAGAGGTCGCTGGA TCGATGGAGATGATGCCTGC	XM_003440029.5	60.03 59.97	150	93.45
grp-78	GTCGAGCAGATTGGAGAGCACAG TCCCCACGTTCTCCTTC	XM_019361056.2	59.83 60.04	116	99.64
ef-1α	CTACGTGACCATCATTGATGCC AACACCAGCAGCAACGATCA	XM_019350634.2	59.45 60.53	106	97.81
β-actin	CAGGATGCAGAAGGAGATCACA CGATCCAGACGGAGTATTTACG	XM_003443127.5	59.83 58.45	92	96.42
ube2	CTCTCAAATCAATGCCACTTCC CCCTGGTGGAGGTTCCTTGT	XM_003460024.5	57.63 61.43	130	102.50

casp-3 cysteine–aspartic acid protease-3, *eif-2a* eukaryotic translation initiation factor 2a, *chop* C/EBP homologous protein, *xbp-1* X-box binding protein 1, *ire-1α* inositol-requiring enzyme 1 alpha, *atf-6* activating transcription factor 6, *grp-78* glucose-regulated protein78, *ef-1α* elongation factor 1-alpha, *β-actin* beta actin, *ube2* ubiquitin conjugating enzyme 2

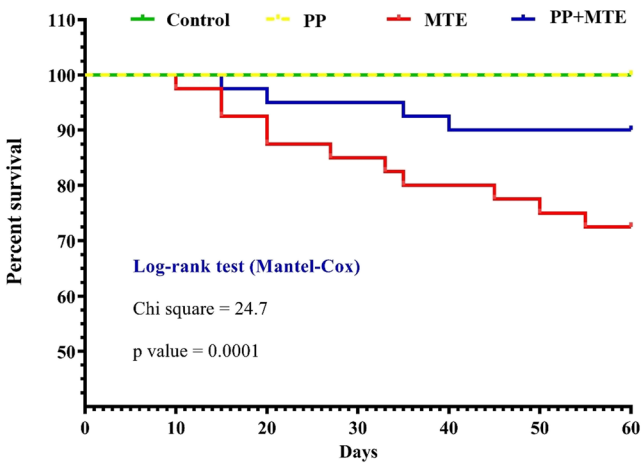

Fig. 1 Survival curves (Kaplan–Meier) of *O. niloticus* after two months of feeding a PP-enriched diet and/or exposure to MTE ($n=40$/group). Control and PP groups: fish were fed on the basal or PP diets, respectively, without MTE exposure. MTE group: fish were exposed to MTE and fed on the basal diet. PP+MTE group: fish were exposed to MTE and fed on the PP diet

for gill genes because of their steady expression levels. To ensure the primer validation, the melting curve analysis was carried out after the amplification. Once the primers' efficiency was confirmed by a nearly 100%, the $2^{-\Delta\Delta CT}$ procedure was used to evaluate the gene expression outcomes. The data were shown as fold changes as recommended in the prior technique (Livak and Schmittgen 2001).

Analysis of data

GraphPad Prism 8 was utilized to examine the significance of differences in survival distribution among treatments via the Kaplan-Meier survival curve and log-rank analysis. The Shapiro–Wilk and Levene's mean testes were carried out to verify the normality and homogeneity of variance of the obtained data. Following that, all variables were tested with a one-way ANOVA using SPSS 21.0 of IBM Corp. (Armonk, USA). In addition, Tukey's HSD was employed to evaluate the mean differences at a significance level of 0.05 ($P<0.05$).

Results

Survivability of fish

Figure 1 illustrates the findings of the Kaplan-Meier assay, showing 100% survival in both the control and PP groups. In contrast, the MTE group registered the lowest survival rate (72.50%), which increased to 87.50% in the PP+MTE group. Significant differences were observed between the groups ($P<0.001$).

Stress/neuro-associated markers

Table 3 presents the stress-related (COR and GLU) and neuro-related (NOR and AchE) biomarkers following a two-month feeding period with a PP-enriched diet and/or exposure to MTE. These variables did not differ significantly between the PP and control groups. However, MTE exposure induced a significant elevation ($P<0.001$) in COR (49.65%), NOR (186.74%), and GLU (49.31%) concentrations, accompanied by a decrease in AchE activity (66.12%) compared to the control group. In fish treated with MTE and supplemented with the PP diet (PP+MTE group), COR (19.54%), NOR (27.43%), and GLU (11.99%) levels were significantly decreased, while AchE activity increased significantly (123.80%), relative to the MTE group ($P<0.001$).

Oxidant/antioxidant markers in gills

The MDA concentration (Fig. 2A) did not differ between the PP and control groups, whereas GPx activity (23.01%; Fig. 2B) and GSH concentration (12.60%; Fig. 2C) were significantly augmented in the PP group ($P < 0.001$). In contrast, the MTE group displayed a markedly higher MDA level (642.98%) and a lower GPx activity (64.70%) and GSH concentration (54.38%) compared to the control ($P < 0.001$). When the PP diet was introduced to the MTE group, the MDA level declined (43.68%) with an elevation in the GPx activity (120.00%) and GSH concentration (51.69%) ($P < 0.001$), comparable to the non-fed exposed group (MTE).

Table 3 Stress and neurochemical markers of O. niloticus after two months of feeding a PP-enriched diet and/or exposure to MTE

Parameters	Control	PP	MTE	PP+MTE	*P*-value
COR (ng/mL)	24.55 ± 0.83^{c}	23.77 ± 0.44^{c}	36.74 ± 1.30^{a}	29.56 ± 0.90^{b}	<0.001
GLU (mg/dL)	76.82 ± 1.62^{c}	73.55 ± 2.63^{c}	114.70 ± 0.98^{a}	100.95 ± 1.12^{b}	< 0.001
NOR (Pg/mL)	70.57 ± 5.44^{c}	76.64 ± 6.72^{c}	202.35 ± 0.95^{a}	146.85 ± 2.80^{b}	< 0.001
AchE (U/L)	86.20 ± 3.58^{a}	88.35 ± 6.15^{a}	29.20 ± 11.08^{c}	65.35 ± 1.52^{b}	<0.001

COR cortisol, *GLU* glucose, *NOR* norepinephrine, *AchE* acetylcholinesterase. Values (mean±*SE*; $n=8$/group) with different superscripts within the same row indicate significant differences (one-way ANOVA, $P<0.05$). Control and PP groups: fish were fed on the basal or PP diets, respectively, without MTE exposure. MTE group: fish were exposed to MTE and fed on the basal diet. PP+MTE group: fish were exposed to MTE and fed on the PP diet

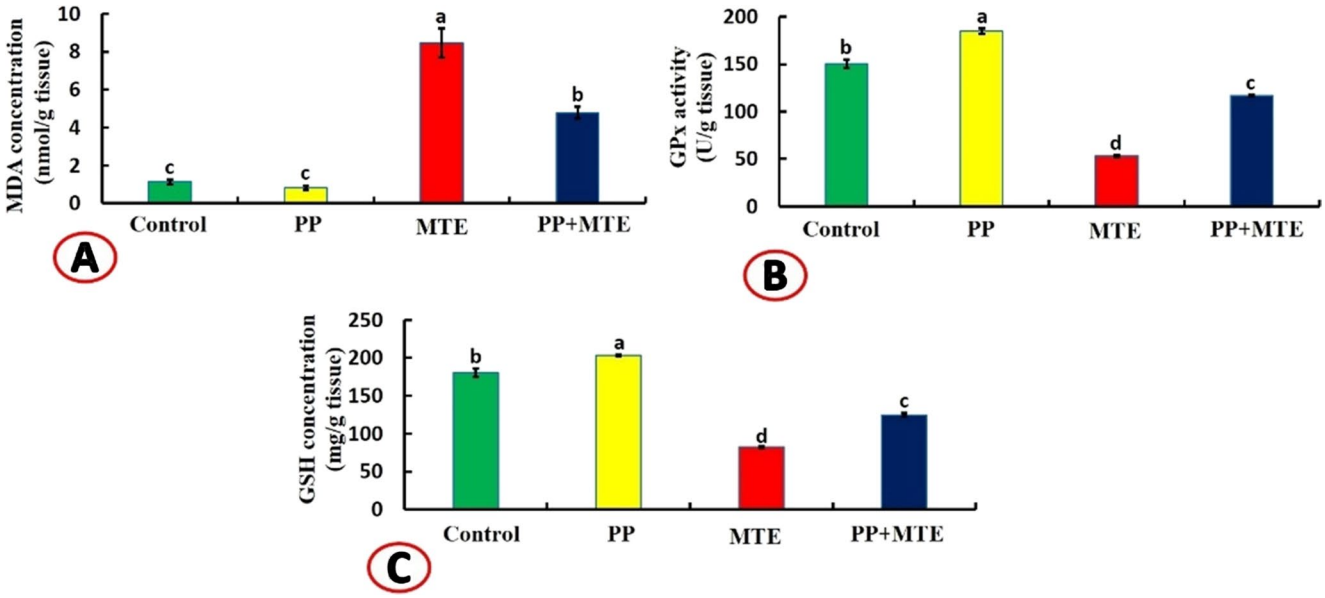

Fig. 2 Oxidant/antioxidant markers in gill tissues of *O. niloticus* after two months of feeding a PP-enriched diet and/or exposure to MTE. **A** MDA: Malondialdehyde. **B** GPx: Glutathione peroxidase. **C** GSH: reduced glutathione content. Bars (mean ± *SE*; $n = 8$/group) with different superscripts within the same row indicate significant differences (one-way ANOVA, $P < 0.05$). Control and PP groups: fish were fed on the basal or PP diets, respectively, without MTE exposure. MTE group: fish were exposed to MTE and fed on the basal diet. PP + MTE group: fish were exposed to MTE and fed on the PP diet

Histopathology

In the control and PP groups (Fig. 3A and B), the brain tissues displayed normal histological architecture, including well-defined neurons, neuropil, and glial cells. In contrast, the brain of the MTE group showed neuropil vacuolations, a moderate number of pyknotic neurons, and congested blood vessels (Fig. 3C). Dietary PP supplementation in the MTE group restored the normal histological structures of the brain (Fig. 3D).

The typical histological architecture of primary and secondary gill lamellae was evident in the gill tissues of the control and PP groups (Fig. 4A and B). On the contrary, the MTE group exhibited detached gill epithelium interspersed with inflammatory cells (Fig. 4C) and moderately engorged gill capillaries. Gill tissues of the PP + MTE group largely retained normal morphology, with most gill filaments appearing intact, although mild detachment of gill epithelium and engorged capillaries were observed in some lamellae (Fig. 4D).

Expression of genes associated with apoptosis and ER-stress pathways

The expression levels of the brain (*casp-3*, *eif-2a*, *chop*, and *xbp-1*) and gill (*ire-1α*, *atf-6*, and *grp-78*) genes related to apoptosis and ER stress after two months of exposure are shown in Figs. 5 and 6. These genes did not show any significant alterations between the PP and control groups. In contrast, MTE exposure resulted in a significant upregulation of these genes compared to the control: *casp-3* (5.97-fold), *eif-2a* (12.04-fold), *chop* (10.23-fold), *xbp-1* (12.95-fold), *ire-1α* (9.94-fold), *atf-6* (7.84-fold), and *grp-78* (12.27-fold) ($P < 0.001$). Conversely, a downregulation trend of these genes was obvious in the PP + MTE group in contrast to the MTE group ($P < 0.001$). The fold changes were 1.99-, 4.93-, 3.37-, 5.25-, 4.27-, 2.35-, and 4.90-fold for the *casp-3*, *eif-2a*, *chop*, *xbp-1*, *ire-1α*, *atf-6*, and *grp-78*, respectively.

Discussion

Aquatic species, particularly fish, are continually exposed to harmful pollutants, such as TE, which contaminate aquatic ecosystems and pose life-threatening risks to both aquatic organisms and the surrounding environment (Khushbu et al. 2022; Shaalan 2024). Recently, herbal feed supplements have been employed to reduce TE toxicity by promoting fish immunity and antioxidant capacity (Fatima et al. 2024). Thus, the present investigation aimed to evaluate the potential efficiency of a PP-fortified diet in palliating the detrimental consequences of MTE involving Hg and Zn on the well-being of *O. niloticus*.

A variety of environmental pollutants, including TE, can induce oxidative stress, which is an imbalance between the creation of free radicals and antioxidant defense mechanisms (Kumar et al. 2024). In the present study, MTE

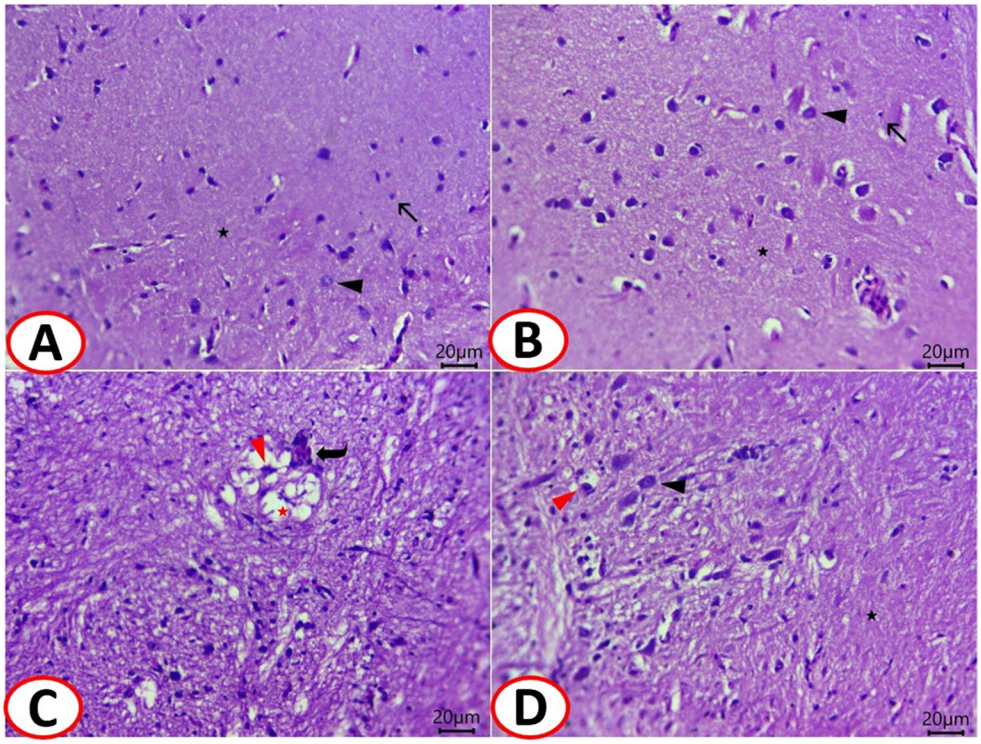

Fig. 3 Representative photomicrographs of brain tissue sections of *O. niloticus* (H&E; scale bar: 20 µm) after two months of feeding a PP-enriched diet and/or exposure to MTE. **A &B** The control and PP groups showing normal histological structures of neurons (black arrowheads), neuropil (stars), and glial cells (black arrows). **C** The MTE group showing moderate neuronal pyknosis (red arrowhead), neuropil vacuolations (red star), and congested blood vessel (curved arrow). **D** The PP+MTE group showing largely normal neurons (black arrowhead), glial cells, and neuropil (star) with few pyknotic neurons (red arrowhead). Control and PP groups: fish were fed on the basal or PP diets, respectively, without MTE exposure. MTE group: fish were exposed to MTE and fed on the basal diet. PP+MTE group: fish were exposed to MTE and fed on the PP diet



Fig. 4 Representative photomicrographs of gill tissue sections of *O. niloticus* (H&E; scale bar: 100 µm) after two months of feeding a PP-enriched diet and/or exposure to MTE. **A &B** control and PP groups showing normal histological architecture of primary gill lamellae (arrows), secondary gill lamellae (arrowheads), and vascular tissues. **C** The MTE group showing detached gill epithelium with inflammatory cells (curved arrow). **D** The PP+MTE group showing largely normal gill filaments with mild epithelial detachment and engorged gill capillaries (thick arrow). Control and PP groups: fish were fed on the basal or PP diets, respectively, without MTE exposure. MTE group: fish were exposed to MTE and fed on the basal diet. PP+MTE group: fish were exposed to MTE and fed on the PP diet

exposure resulted in elevated levels of MDA (lipid peroxides) and decreased GPx and GSH (antioxidant defenses) in the gills. These findings highlight the detrimental effects of MTE bioaccumulation (Hg and Zn) on fish gills, leading to impaired synthesis of antioxidant enzymes and persistent oxidative damage. According to Chavan and Muley (2014), prolonged exposure of fish to TE exerted harmful impacts on the most directly exposed organ (gills). The histopathological alterations observed in the gills in the results support these findings.

The oxidative damage and weakened antioxidant defenses induced by Hg may be mediated through a variety

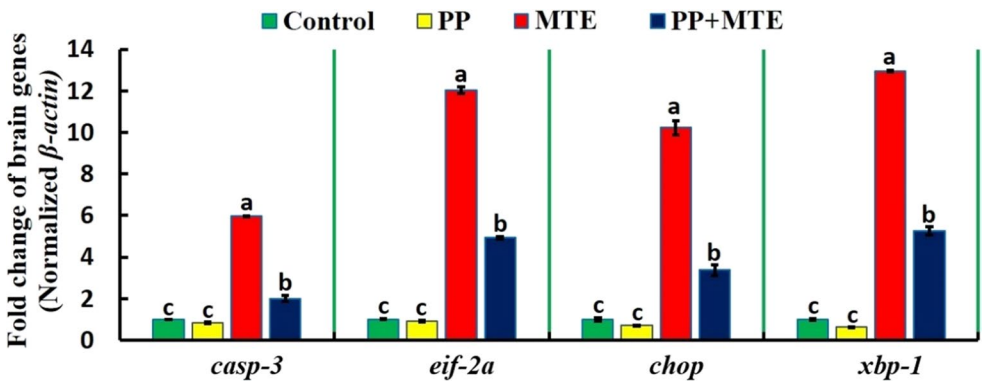

Fig. 5 Expression of apoptosis and endoplasmic reticulum stress-related chaperones in the brain of *O. niloticus* after two months of feeding a PP-enriched diet and/or exposure to MTE. *casp-3*: cysteine–aspartic acid protease-3. *eif-2a*: eukaryotic translation initiation factor 2a. *chop*: C/EBP homologous protein. *xbp-1*: x-box binding protein 1. Bars (mean ± *SE*; *n* = 8/group) with different superscripts within the same row indicate significant differences (one-way ANOVA, $P < 0.05$). Control and PP groups: fish were fed on the basal or PP diets, respectively, without MTE exposure. MTE group: fish were exposed to MTE and fed on the basal diet. PP + MTE group: fish were exposed to MTE and fed on the PP diet

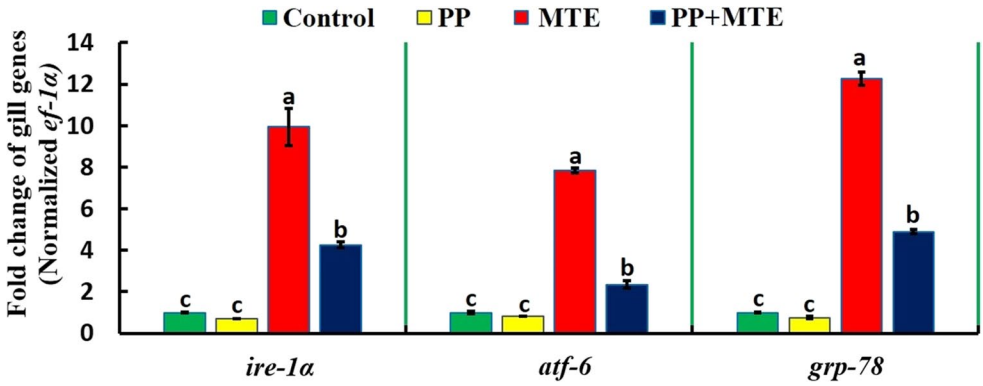

Fig. 6 Expression of endoplasmic reticulum stress-related chaperones in the gills of *O. niloticus* after two months of feeding a PP-enriched diet and/or exposure to MTE. *ire-1α*: inositol-requiring enzyme 1 alpha. *atf-6*: activating transcription factor 6. *grp-78*: glucose-regulated protein78. Bars (mean ± *SE*; *n* = 8/group) with different superscripts within the same row indicate significant differences (one-way ANOVA, $P < 0.05$). Control and PP groups: fish were fed on the basal or PP diets, respectively, without MTE exposure. MTE group: fish were exposed to MTE and fed on the basal diet. PP + MTE group: fish were exposed to MTE and fed on the PP diet

of mechanisms. One pathway of Hg toxicity involves its strong binding affinity with thiol groups in antioxidant enzymes and glutathione, leading to enzyme inactivation, GSH depletion, and hindering their ability to neutralize ROS (Rupa et al. 2023). Furthermore, Hg disrupts mitochondrial membranes and inhibits enzymes within the mitochondria's electron transport chain, thereby promoting excessive ROS formation. This, in turn, leads to protein and lipid peroxidation (evidenced by elevated MDA levels), ultimately triggering inflammatory and apoptotic pathways in fish tissues (Baldissera et al. 2019). Moreover, Zn is a necessary micronutrient for several enzymatic and cellular processes for fish health and growth (Xu et al. 2023). However, at elevated concentrations, Zn becomes hazardous by displacing copper and iron (essential metals) from proteins and enzymes, thereby impairing their functions, and destabilizing antioxidant mechanisms (Prasad and Bao 2019). Additionally, excessive Zn accumulates in mitochondria, disrupting the mitochondrial membrane and causing electron leakage, which leads to ROS creation and subsequent damage to lipids and DNA (Xia et al. 2023).

These outcomes are consistent with prior investigations on individual exposure to Hg and Zn. For example, Hg concentrations of 0.022 mg/L for 42 days (Waheed et al. 2020) and 0.30 mg/L for 21 days (Zahran et al. 2024) in *O. niloticus* induced decreased antioxidant defenses, including superoxide dismutase (SOD), GPx, and CAT. Similarly, *O. niloticus* subjected to Zn concentrations of 2.00 mg/L for 15 days (Saddick et al. 2017) and 7.00 mg/L for 12 weeks (Abd El-Naby et al. 2020) showed increased MDA levels and reduced activities of GPx, SOD, and CAT, along with lower GSH concentrations.

Interestingly, supplementation of the PP-fortified diet in the MTE-exposed group led to a decrease in the MDA

concentration and a significant restoration of antioxidant status as indicated by increased GPx activity and GSH levels. These effects may be attributed to the potent antioxidant capacity of PP, which is linked to its active phytochemicals. As reported in our previous study (Ibrahim et al. 2025b), PP contains considerable amounts of flavonoids (2.72%) and phenolics (0.26%), both of which contribute to its antioxidant potential (Cvetković et al. 2021). In addition, PP is rich in flavonols, vitamin C, carotenoids, and polyphenols, all of which enhance its antioxidant characteristics (Peiretti et al. 2017; Kulczyński et al. 2020). According to Kumar and Goel (2019), the strong antioxidant activity of phenolics is primarily achieved through radical scavenging mechanisms involving hydrogen atom donation. Moreover, the flavonoids can chelate metal ions, enhance the endogenous antioxidant defenses, and scavenge free radicals (Hassanpour and Doroudi 2023). The notable restoration of gill histoarchitecture observed in the co-exposed group (PP+MTE) further supports this interpretation. Consistent with a prior report (Ibrahim et al. 2025a), dietary PP supplementation could protect the spleen, liver, and kidneys of *O. niloticus* from TE toxicity by its antioxidant power.

Monitoring tissue-specific gene expression provides valuable insights into how organisms respond to environmental contaminants (Gupta et al. 2025). In this study, we observed an upregulation of ER stress-related genes (*eif-2a*, *chop*, *xbp-1*, *ire-1α*, *atf-6*, and *grp-78*), as well as the apoptosis-related gene (*casp-3*) of the brain and gills. This indicates that exposure to both Hg and Zn induced ER stress and apoptotic responses. These findings are in line with previous studies following individual exposures to various concentrations of Hg or Zn.

For example, exposure to Hg concentrations of 0.039 mg/L and 0.078 mg/L for 45 days induced oxidative damage, genotoxicity, and apoptosis in *Channa punctatus* (Singh et al. 2024). Similarly, in mouse neurons, apoptosis and neuronal oxidative injury, along with the activation of protein kinase RNA-like ER kinase (*perk*), *ire-1α*, and *chop* pathways, were observed following exposure to 30 and 50 mg/L Hg for 35 days (Nomura et al. 2022), confirming the induction of ER stress. In fish (*P. fulvidraco*), exposure to 0.50 mg/L Zn for 56 days also triggered ER stress and UPR activation, as evidenced by the upregulation of *grp-78*, *perk*, *eif-2a*, *xbp-1*, *atf-6*, *chop*, and *ire-1α* genes (Song et al. 2017).

The hypothesized mechanism underlying these findings may involve the accumulation of Hg and Zn in fish tissues (brain and gills), which produce ROS leads to oxidative stress as previously discussed. Such oxidative damage disrupts ER function, promotes the accumulation of misfolded proteins, and activates the UPR (Demircan et al. 2024). This activation upregulates ER stress–related signaling molecules, including *grp-78*, spliced *xbp-1*, *ire-1α*, *atf-6*, and *perk* through *eif-2a*. Subsequently, these pathways stimulate the transcription of *chop* and *casp-12*, leading to mitochondrial malfunction and stimulation of *casp-3* (Song et al. 2017; Chung et al. 2019).This cascade ultimately initiates apoptotic pathways and results in structural degeneration of vital organs (Rana 2020). These interpretations are supported by the histopathological alterations observed in the gill and brain of the MTE-exposed fish and by the reduction in their survival rate (72.50%). Nevertheless, further assessment of TE residues is warranted to confirm these findings.

Conversely, giving the PP diet to the MTE-exposed group led to downregulation of ER stress–related genes, improved histological architecture of the brain and gills, and increased survival rate (87.50%). These protective effects can be attributed to the bioactive compounds in PP, including phenolics, flavonoids, and oleic acid, which have antioxidant and anti-inflammatory properties. Phenolics and flavonoids effectively scavenge ROS, thereby reducing oxidative load on ER, motivating the expression of antioxidant genes, and restoring cellular redox balance (Almohaimeed et al. 2021; Fathima et al. 2024). In addition, oleic acid supports mitochondrial-ER interaction and stabilizes lipid membranes, which decreases ROS production and alleviates ER membrane stress (Song et al. 2019; Balgoon et al. 2021). In addition, these bioactive compounds can suppress the expression of pro-inflammatory/inflammatory cytokines and nuclear factor kappa B, which is implicated in the propagation of ER stress (Ben-Dror and Birk 2019; Amin et al. 2020). Through these mechanisms, they may mitigate ER stress and apoptosis mediated by MTE exposure.

Consistently, Ibrahim et al. (2025b) reported that dietary PP downregulated genes linked with apoptosis and DNA damage in *O. niloticus*, demonstrating its tissue-protective potential. Similarly, dietary supplementation with ascorbic acid and *Nannochloropsis oculata* (10 g/kg diet) reduced the expression of the apoptotic gene (*casp-3*) and stress-related gene (heat shock protein) of *C. punctatus* and *O. niloticus* subjected to Hg at 0.10 mg/L for 15 days and 0.30 mg/L for 21 days, respectively (Singh et al. 2020; Zahran et al. 2024).

Prolonged exposure to pollutants, such as TE, has significant physiological effects on fish (Shahjahan et al. 2022). In this study, extended exposure to MTE (Hg and Zn) acted as a physiological stressor, as evidenced by increased concentrations of stress markers (COR, NOR, and GLU). This stress activated the sympathetic–chromaffin axis, leading to NOR release, which in turn indirectly stimulated the hypothalamic-pituitary-interrenal axis to produce COR (the main fish glucocorticoid). This hormonal response (elevated NOR and COR) facilitated energy mobilization to help fish cope with the challenges of MTE exposure (Li et al. 2021). As a result, glycogenolysis and gluconeogenesis in the liver

were enhanced, elevating blood GLU levels (Lelou et al. 2022). Furthermore, TE contamination may disrupt GLU metabolism by impairing phosphorylation and oxidation processes, leading to an accumulation of GLU in tissue cells (Javed and Usmani 2015; Gupta et al. 2025). Comparable responses (high COR and GLU levels) have been reported in *O. niloticus* exposed to Hg (0.084 mg/L for 30 days) and Zn (7.00 mg/L for 6 weeks), as stated by Reda et al. (2025) and Abdel-Tawwab et al. (2016).

In this study, stress parameters (COR, GLU, and NOR) were reduced in the MTE-exposed group supplemented with a PP diet. This highlights PP's protective role in alleviating stress, supporting liver glycogen reserves, and exerting anti-inflammatory effects during prolonged MTE exposure. These effects are likely attributable to the phytochemicals in PP (estradiol, palmitic acid, and oleic acid), which possess anti-stress, anti-inflammatory, and antioxidant properties (Almohaimeed et al. 2021). These results are consistent with previous studies in albino rats administered oral pumpkin fruit extract for 14 days and Wistar albino rats given pumpkin seeds orally for 8 weeks (Ayuob et al. 2021; Chenni et al. 2022), where decreased corticosterone (a primary glucocorticoid indicator for stress) and GLU levels were observed.

AchE activity is considered a valuable biomarker for assessing recurrent and persistent toxicant exposure (Alves et al. 2020). Our findings indicated that MTE reduced AchE activity, leading to elevated acetylcholine levels at synaptic junctions. This increase in cholinergic signaling may enhance the activation of muscle and nerve fibers, ultimately resulting in neurobehavioral alterations (Jebali et al. 2013; Şen and Karaytuğ 2017). However, this study did not include detailed monitoring of fish behavior or other neurochemical endpoints, which could provide further insights into the neurotoxic effects of MTE. The observed effects may be attributed to the bioaccumulation of toxic elements (Hg and Zn) in the brain tissue and the generation of ROS, causing oxidative damage and ER stress in neurons, ultimately leading to synaptic dysfunction (Rani et al. 2015; de Castro Rodrigues et al. 2018). The upregulation of ER stress-related genes and brain histopathological changes observed in our results support this explanation. Previous reports of Reda et al. (2025) and Sarasamma et al. (2018) are consistent with our findings, showing that *O. niloticus* exposed to Hg (0.084 mg/L for 30 days) and zebrafish (*Danio rerio*) exposed to Zn (1.50 mg/L for 21 days) exhibited decreased AchE activity.

Conversely, supplementation with PP enhanced brain function by improving AchE activity during MTE exposure. This underscores the effectiveness of dietary PP in protecting against TE bioaccumulation through its potent antioxidant and anti-inflammatory properties, as described above. The AchE-restoring potential of PP, attributed to its flavonoids, beta-tocopherol, and phenolic content, has been reported in albino rats treated with haloperidol (used to induce Parkinson's), confirming its neuroprotective effects (Saleem et al. 2021). Furthermore, Ezebuilo et al. (2023) demonstrated the reestablishment of AchE activity through oral administration of PP in tramadol-intoxicated albino rats, mediated by its antioxidant constituents (methyl-thyl ester and pentadecanoic acid). In *O. niloticus*, similar findings were observed with a different feed additive: Hg exposure caused a significant decrease in AchE activity, whereas dietary *N. oculata* improved its level (Zahran et al. 2024).

Conclusion

Overall, combined exposure of Hg and Zn caused oxidative stress and upregulation of ER stress and apoptotic genes in *O. niloticus*. Additionally, it induced histopathological alterations in the brain and gill tissues and reduced fish survivability (27.50%). Dietary supplementation with PP (12.00 g/kg) mitigated the harmful impacts of this combined exposure, including improved survival rate (87.50%) and antioxidant status, reduced stress responses, and preserved tissue architectures. Nonetheless, several limitations should be addressed in future studies, such as evaluating additional health endpoints. For example, monitoring fish behavior, assessing other neurochemical parameters, and measuring Hg and Zn residues in the brain, gills, and muscles could pose further health risks to humans. Moreover, additional research is needed to assess the efficacy of PP as a water additive in reducing the detrimental effects of pollutant exposure in aquatic species.

Acknowledgements This work was supported by the Deanship of Scientific Research, Vice Presidency for Graduate Studies and Scientific Research, King Faisal University, Saudi Arabia [Grant No. KFU251426]. The authors thank the Aquatic Animal Medicine Department, Faculty of Veterinary Medicine, Zagazig University, for their help during the experimental procedures.

Author contributions A.N.A.: Conceptualization, Data curation, Formal analysis, Investigation, Methodology, Resources, Validation, Visualization, Writing – original draft, Writing – review & editing. M.S.S., T.K.: Data curation, Formal analysis, Validation, Visualization, Writing – review & editing. A.T.M., A.S.A., Y.A., H.A.H., A.A.: Investigation, Resources, Funding acquisition, Writing – review & editing. R.E.I.: Conceptualization, Investigation, Methodology, Resources, Visualization, Writing – review & editing. S.T.E.: Conceptualization, Investigation, Resources, Writing – review & editing. All authors have read and agreed to the published version of the manuscript.

Funding This work was supported by the Deanship of Scientific Research, Vice Presidency for Graduate Studies and Scientific Research, King Faisal University, Saudi Arabia [Grant No. KFU251426].

Data availability All data generated or analyzed during this study are included in this article.

Declarations

Ethics approval All research procedures in this study were approved by the Zagazig University Authority for Animal Use in Research (ZU-IACUC/2/F/4/2024), Egypt. The study was conducted in compliance with the ARRIVE guidelines, and all methods were performed following the relevant guidelines and regulations.

Consent for publication All authors review and approve the manuscript for publication.

Consent to participate All authors have participated in this work.

Competing interests The authors declare no competing interests.

References

Abd El-Naby AS, El Asely AM, Amin AA, Samir F, El-Ashram A, Dawood MAO (2020) Miswak (*Salvadora persica*) modulated the growth performance, antioxidative response, and histopathological damage induced by zinc toxicity in nile tilapia (*Oreochromis niloticus*). Environ Sci Pollut Res Int 27:31918–31932. https://doi.org/10.1007/s11356-020-09429-1

Abdel-Baky TE, Hagras AE, Hassan SH, Zyadah MA (1998) Environmental impact assessment of pollution in Lake Manzala, I. Distribution of some heavy metals in water and sediment. J Egypt Ger Soc Zool 26:25–38

Abdel Rahman AN, AbdelMageed M, Assayed A, Gharib MEM, Nasr HSA, Elshopakey MA GE et al (2023) Imidacloprid induced growth, hematological, neuro-behavior, anti-oxidant, economic, genetic, and histopathological alterations in *Clarias gariepinus*: alleviative role of dietary *Hyphaene Thebaica*. Aquaculture 564:739058. https://doi.org/10.1016/j.aquaculture.2022.739058

Abdel Rahman AN, Mahboub HH, Ezz-Eldin RMM, Abdelwarith AA, Younis EM, Khamis T et al (2025) Lead toxicity in African catfish: promising role of magnetite nanogel against ethoneurological alterations, antioxidant suppression, gene toxicity, and histopathological/ immunohistochemical disruptions. Aquaculture 594:741411. https://doi.org/10.1016/j.aquaculture.2024.741411

Abdel-Tawwab M, Shalaby AME, Ahmad MH, Khattab YAE (2004) Effect of supplemental dietary L-ascorbic acid (vitamin C) on mercury detoxication, physiological aspects and growth performance of nile tilapia (*Oreochromus niloticus* L). Ann Agric Sci 39:883–895

Abdel-Tawwab M, El-sayed GO, Shady SHH, Liping L, Fitzsimmons K (2011) Acute toxicity of water-born zinc in Nile tilapia, *Oreochromis niloticus* (L.) fingerlings. In: (eds) LLaKF (ed) Proceedings of the ninth International Symposium on Tilapia in Aquaculture, Shanghai Ocean University, Shanghai, China, pp 39–44

Abdel-Tawwab M, El-Sayed GO, Shady SH (2016) Growth, biochemical variables, and zinc bioaccumulation in nile tilapia, *Oreochromis niloticus* (L.) as affected by waterborne zinc toxicity and exposure period. Int Aquat Res 8:197–206. https://doi.org/10.1007/s40071-016-0135-0

Adam MA, Soegianto A, Risjani Y, Payus CM, Yoga RGP, Sadi NH et al (2023) The cortisol levels, histology, and fine structure of various tissues of fish Gambusia affinis (Baird and Girard, 1853) after exposure to lead. Scientifica 2023:6649258. https://doi.org/10.1155/2023/6649258

Akubugwo EI, Emmanuel O, Ekweogu CN, Ugbogu OC, Onuorah TR, Egeduzu OG et al (2022) GC-MS analysis of the phytochemical constituents, safety assessment, wound healing and anti-inflammatory activities of *Cucurbita Pepo* leaf extract in rats. Sci Pharm 90:64. https://doi.org/10.3390/scipharm90040064

Alkaladi A (2019) Vitamins E and C ameliorate the oxidative stresses induced by zinc oxide nanoparticles on liver and gills of *Oreochromis niloticus*. Saudi J Biol Sci 26:357–362. https://doi.org/10.1016/j.sjbs.2018.07.001

Almanza A, Carlesso A, Chintha C, Creedican S, Doultsinos D, Leuzzi B (2019) Endoplasmic reticulum stress signalling - from basic mechanisms to clinical applications. FEBS J 286:241–278. https://doi.org/10.1111/febs.14608

Almohaimeed HM, Hamed S, Seleem HS, Batawi AH, Mohammedsaleh ZM, Balgoon MJ et al (2021) An ethanolic extract of *Cucurbita Pepo* L. seeds modifies neuroendocrine disruption in chronic stressed rats and adrenal expression of inflammatory markers and HSP70. Front Pharmacol 12:749766. https://doi.org/10.3389/fphar.2021.749766

Alves H, Silva A, Pavão J, Matos-Rocha T, Souza M, Costa J et al (2020) The acetylcholinesterase as indicative of intoxication for pesticide in farmers of conventional and organic cultivation. Braz J Biol 81:632–641. https://doi.org/10.1590/1519-6984.227875

Amin MZ, Rity TI, Uddin MR, Rahman MM, Uddin MJ (2020) A comparative assessment of anti-inflammatory, anti-oxidant and anti-bacterial activities of hybrid and Indigenous varieties of pumpkin (*Cucurbita maxima* Linn.) seed oil. Biocat Agric Biotechnol 28:101767. https://doi.org/10.1016/j.bcab.2020.101767

AOAC (2005) Official Methods of Analysis of Association of Official Analysis of Chemist. eighteenth edn. Association of Official Analytical Chemists, Maryland, USA

APHA (2005) Standard methods for examination of water and wastewater, 21th edn. edn. American Public Health Association, American Water Works Association, Water Pollution Control Federation, New York

AVMA (2007) Guidelines on Euthanasia (Formerly the Report of the AVMA Panel on Euthanasia)

Ayuob N, Shaker SA, Hawuit E, Al-Abbas N, Shaer N, Al Jaouni S et al (2021) *L. Cucurbita Pepo* alleviates chronic unpredictable mild stress via modulation of apoptosis, neurogenesis, and gliosis in rat hippocampus. Oxid Med Cell Longev 2021:6662649. https://doi.org/10.1155/2021/6662649

Azevedo LS, Pestana I, da Costa Nery A, Bastos W, Souza C (2019) Variation in hg accumulation between demersal and pelagic fish from Puruzinho Lake, Brazilian Amazon. Ecotoxicol 28:1143–1149. https://doi.org/10.1007/s10646-019-02118-x

Baldissera MD, Souza CF, Grings M, Descovi SN, Henn AS, Flores EMM et al (2019) Exposure to Methylmercury chloride inhibits mitochondrial electron transport chain and phosphotransfer network in liver and gills of grass carp: protective effects of Diphenyl diselenide dietary supplementation as an alternative strategy for mercury toxicity. Aquaculture 509:85–95. https://doi.org/10.1016/j.aquaculture.2019.05.012

Balgoon M, Al-Zahrani M, Jaouni S, Ayuob N (2021) Combined oral and topical application of pumpkin (*Cucurbita Pepo* L.) alleviates contact dermatitis associated with depression through downregulation pro-inflammatory cytokines. Front Pharmacol 12:663417. https://doi.org/10.3389/fphar.2021

Bella CD, Calagna A, Cammilleri G, Chembri P, Monaco DL, Ciprì V et al (2021) Risk assessment of cadmium, lead, and mercury on human health in relation to the consumption of farmed sea bass in italy: a meta-analytical approach. Front Mar Sci 8:616488. https://doi.org/10.3389/fmars.2021.616488

Ben-Dror K, Birk R (2019) Oleic acid ameliorates palmitic acid-induced ER stress and inflammation markers in Naive and cerulein-treated exocrine pancreas cells. Biosci Rep 39:BSR20190054. https://doi.org/10.1042/BSR20190054

Beutler M, Duron O, Kelly BM (1963) Improved method for the determination of blood glutathione. J Lab Clin Med 61:882–888

Bhuyan MS, Bakar MA (2017) Seasonal variation of heavy metals in water and sediments in the Halda River, Chittagong, Bangladesh. Environ Sci Pollut Res 24:27587–27600. https://doi.org/10.1007/s11356-017-0204-y

Bowen L, Werner I, Johnson ML (2006) Physiological and behavioral effects of zinc and temperature on Coho salmon (*Oncorhynchus kisutch*). Hydrobiol 559:161–168

Caglayan C, Kandemir FM, Darendelioğlu E, Yıldırım S, Kucukler S, Dortbudak MB (2019) Rutin ameliorates mercuric chloride-induced hepatotoxicity in rats via interfering with oxidative stress, inflammation and apoptosis. J Trace Elem Med Biol 56:60–68. https://doi.org/10.1016/j.jtemb.2019.07.011

Chavan V, Muley D (2014) Effect of heavy metals on liver and gill of fish *Cirrhinus Mrigala*. Int J Curr Microbiol App Sci 3:277–288

Chen X, Bao J, Guo J, Ding Q, Lu J, Huang M et al (2012) Biological activities and potential molecular targets of cucurbitacins: a focus on cancer. Anticancer Drugs 23(8):777–787. https://doi.org/10.11964/jfc.20200612309

Chenni A, Cherif FZH, Chenni K, Elius E, Pucci L, Yahia D (2022) Effects of pumpkin (*Cucurbita Pepo* L.) seed protein on blood pressure, plasma lipids, leptin, adiponectin, and oxidative stress in rats with fructose-induced metabolic syndrome. Prev Nutr Food Sci 27(1):78–88. https://doi.org/10.3746/pnf.2022.27.1.78

Chung YP, Yen CC, Tang FC, Lee KI, Liu SH, Wu CC et al (2019) Methylmercury exposure induces ROS/Akt inactivation-triggered Endoplasmic reticulum stress-regulated neuronal cell apoptosis. Toxicology 425:152245. https://doi.org/10.1016/j.tox.2019.152245

Ciosek Ż, Kot K, Rotter I (2023) Iron, zinc, copper, cadmium, mercury, and bone tissue. Int J Environ Res Public Health 20:2197. https://doi.org/10.3390/ijerph20032197

Cvetković D, Stanojević L, Zvezdanović J, Stanojević J, Savić D, Karabegović I et al (2021) Pumpkin fruit (*Cucurbita Pepo* L.) as a source of phytochemicals useful in food and pharmaceutical industries. J Food Measur Charact 15(5):4596–4607. https://doi.org/10.1007/s11694-021-01014-5

de Castro Rodrigues A, Carvalheira R, Gomes V, Arias A, Almosny N, Castilhos Z et al (2018) Acetylcholinesterase activity in fish exposed to mercury in Guanabara Bay, RJ, Brazil. Envi Poll Prot 3:91–99. https://doi.org/10.22606/epp.2018.34001

Demircan N, Ozgur R, Turkan I, Uzilday B (2024) Heavy metal toxicity leads to accumulation of insoluble proteins and induces Endoplasmic reticulum stress-specific unfolded protein response in *Arabidopsis Thaliana*. Environ Sci Pollut Res Int 31:53206–53218. https://doi.org/10.1007/s11356-024-34780-y

El-Sappah AH, Seif MM, Abdel-Kader HH, Soaud SA, Elhamid MAA, Abdelghaffar AM, El-Sappah HH, Sarwar H, Yadav V, Maitra P, Zhao X, Yan K, Li J, Abbas M (2022) Genotoxicity and trace elements contents analysis in Nile tilapia (Oreochromis niloticus) indicated the levels of aquatic contamination at three Egyptian areas. Front Vet Sci 9:818866. https://doi.org/10.3389/fvets.2022.818866

El-Sayed A-FM, Fitzsimmons K (2023) From Africa to the world—The journey of nile tilapia. Rev Aquac 15:6–21. https://doi.org/10.1111/raq.12738

Ezebuilo UE, Udeh KU, Ezumezu CP (2023) Prophylactic effect of cucurbita Pepo seed oil on brain acetylcholinesterase and ATPases (Na+/K+and Ca2+) activities of tramadol-induced toxicity in albino rats. Int J Sci Res 2:157–164

Fathima S, Firdous S, Pal S, Ghazzawy H, Gouda M (2024) Assessment of in vitro antioxidant and anti-inflammatory activities of pumpkin (*Cucurbita pepo*) natural plant. Nat Prod Commun 19. https://doi.org/10.1177/1934578X241257127

Fatima A, Makhdoom Hussain S, Ali S, Rizwan M, Al-Ghanim KA, Yong JWH (2024) Ameliorating effects of natural herbal supplements against water-borne induced toxicity of heavy metals on nile tilapia, (*Oreochromis niloticus*). Sci Rep 14:22571. https://doi.org/10.1038/s41598-024-72268-4

Fred-Ahmadu OH, Ahmadu FO, Adedapo AE, Oghenovo I, Ogunmodede OT, Benson NU (2024) Microplastics and chemical contamination in aquaculture ecosystems: the role of climate change and implications for food safety—a review. Environ Sci Eur 36:181. https://doi.org/10.1186/s12302-024-00995-6

Gohari AA, Farhoosh R, Haddad KM (2011) Chemical composition and physicochemical properties of pumpkin seeds (*Cucurbita Pepo* Subsp. *Pepo* Var. *Styriaka*) grown in Iran. J Agr Sci Tech 13:1053–1063

Gupta SK, Gupta R, Nage S, Kumar N, Kumari R, Gupta A et al (2025) Heavy metal accumulation and biomarker responses of nile tilapia from a coal void reservoir cage aquaculture system. J Hazard Mater Adv 18:100631. https://doi.org/10.1016/j.hazadv.2025.100631

Hama Aziz KH, Mustafa FS, Omer KM, Hama S, Hamarawf R, Rahman K (2023) Heavy metal pollution in the aquatic environment: efficient and low-cost removal approaches to eliminate their toxicity: a review. RSC Adv 13(26):17595–17610. https://doi.org/10.1039/d3ra00723e

Hassanpour SH, Doroudi A (2023) Review of the antioxidant potential of flavonoids as a subgroup of polyphenols and partial substitute for synthetic antioxidants. Avicenna J Phytomed 13(4):354–376. https://doi.org/10.22038/AJP.2023.21774

Hogstrand C (2011) Zinc. Academic, New York, USA

Ibrahim RE, Ghamry HI, Althobaiti SA, Almalki DA, Shakweer MS, Hassan MA et al (2023) *Moringa Oleifera* and *Azadirachta indica* leaves enriched diets mitigate chronic oxyfluorfen toxicity induced immunosuppression through disruption of pro/anti-inflammatory gene pathways, alteration of antioxidant gene expression, and histopathological alteration in *Oreochromis niloticus*. Fishes 8:15. https://doi.org/10.3390/fishes8010015

Ibrahim RE, Abdel Rahman AN, Sobh MS, Mansour AT, Alsaqufi AS, Alkhamis Y et al (2025a) Pumpkin Peel (*Cucurbita pepo*)–fortified diet mitigates trace element mixture (mercury and zinc)–induced hepato-renal dysfunction, immunotoxicity, Splenic gene disruption, and histopathological alterations in *Oreochromis niloticus*. Fish Physiol Biochem 51:120. https://doi.org/10.1007/s10695-025-01534-7

Ibrahim RE, Elshopakey GE, Younis EM, Abdelwarith AA, Yaseen A, Khamis T et al (2025b) Peel of pumpkin (*Cucurbita pepo*) diets boost growth, digestive-absorptive functions, immune-antioxidant indices, and regulate Immunomodulatory genes and mTOR/MAPK-P38/apoptosis signaling pathway in *Oreochromis niloticus*. Aquac Rep 40:102548. https://doi.org/10.1016/j.aqrep.2024.102548

Javed M, Usmani N (2015) Impact of heavy metal toxicity on hematology and glycogen status of fish: A review. Proc Natl Acad Sci India Sect B Biol Sci 85(4):889–900. https://doi.org/10.1007/s40011-014-0404-x

Jebali J, Khedher SB, Sabbagh M, Kamel N, Banni M, Boussetta H (2013) Cholinesterase activity as biomarker of neurotoxicity: utility in the assessment of aquatic environment contamination. J Integr Coast Zone Manag 13:525–537

Karamać M (2009) Chelation of Cu(II), Zn(II), and Fe(II) by tannin constituents of selected edible nuts. Int J Mol Sci 10:5485–5497. https://doi.org/10.3390/ijms10125485

Karataş B (2024) Dietary *Cyanus depressus* (M. Bieb.) Soják plant extract enhances growth performance, modulates intestinal microbiota, and alters gene expression associated with digestion, antioxidant, stress, and immune responses in rainbow trout (*Oncorhynchus mykiss*). Aquac Int 32(6):7929–7951. https://doi.org/10.1007/s10499-024-01548-7

Khalil MT, Gad NS, Ahmed NAM, Moustafa SS (2017) Antioxidant defense system alternations in fish as a bio-indicator of environmental pollution Egypt. J Aquat Biol Fish 21:11–28

Khushbu GR, Sushma, Kour A, Sharma P (2022) Ecological impact of heavy metals on aquatic environment with reference to fish and human health. J Nat Appl Sci 14:1471–1484. https://doi.org/10.31018/jans.v14i4.3900

Kim MY, Kim EJ, Kim Y-N, Choi C, Lee B-H (2012) Comparison of the chemical compositions and nutritive values of various pumpkin (*Cucurbitaceae*) species and parts. Nutr Res Pract 6:21–27. https://doi.org/10.4162/nrp.2012.6.1.21

Kim J-H, Choi H, Sung G, Seo S-A, Kim KI, Kang YJ et al (2019) Toxic effects on hematological parameters and oxidative stress in juvenile Olive flounder, *Paralichthys Olivaceus* exposed to waterborne zinc. Aquac Rep 15:100225. https://doi.org/10.1016/j.aqrep.2019.100225

Kim MJ, Park J, Kim J, Kim JY, An MJ, Shin GS et al (2021) Transcriptome analysis reveals $HgCl_2$ induces apoptotic cell death in human lung carcinoma H1299 cells through caspase-3-independent pathway. Int J Mol Sci 222: 2006. https://doi.org/10.3390/ijms22042006

Kulczyński B, Sidor A, Gramza-Michałowska A (2020) Antioxidant potential of phytochemicals in pumpkin varieties belonging to *Cucurbita moschata* and *Cucurbita Pepo* species. CyTA-J Food 18:472–484. https://doi.org/10.1080/19476337.2020.1778092

Kumar N, Goel N (2019) Phenolic acids: natural versatile molecules with promising therapeutic applications. Biotechnol Rep 24:e00370

Kumar M, Singh S, Jain A, Yadav S, Dubey A, Trivedi SP (2024) A review on heavy metal-induced toxicity in fishes: Bioaccumulation, antioxidant defense system, histopathological manifestations, and transcriptional profiling of genes. J Trace Elem Med Biol 83:127377. https://doi.org/10.1016/j.jtemb.2023.127377

Kwon MJ, Boyanov MI, Mishra B, Kemner KM, Jeon S-k, Hong JK et al (2022) Zn speciation and fate in soils and sediments along the ground transportation route of Zn ore to a smelter. J Hazard Mater 438:129422. https://doi.org/10.1016/j.jhazmat.2022.129422

Lee C-L, Kominami Y, Ushio H (2021) Mechanism of delayed convulsion in fish: the actions of norepinephrine in spinal cord. Fishes 6:12. https://doi.org/10.3390/fishes6020012

Lelou E, Corlu A, Nesseler N, Rauch C, Mallédant Y, Seguin P et al (2022) The role of catecholamines in pathophysiological liver processes. Cells 11:1021. https://doi.org/10.3390/cells11061021

Li M, Kong Y, Wu X, Yin Z, Niu X, Wang G (2021) Dietary α-lipoic acid can alleviate the bioaccumulation, oxidative stress, cell apoptosis, and inflammation induced by lead (Pb) in *Channa Argus*. Fish Shellfish Immunol 119:249–261. https://doi.org/10.1016/j.fsi.2021.10.010

Livak KJ, Schmittgen TD (2001) Analysis of relative gene expression data using real-time quantitative PCR and the 2(-Delta delta C(T)) method. Methods 25:402–408

Mahi TF, Chowdhury G, Hossain MA, Baishnab AK, Schneider P, Iqbal MM (2022) Assessment of lead (Pb) toxicity in juvenile nile tilapia, *Oreochromis niloticus*—growth, behaviour, erythrocytes abnormalities, and histological alterations in vital organs. Toxics 10:793. https://doi.org/10.3390/toxics10120793

Mellingen RM, Myrmel LS, Rasinger JD, Lie KK, Bernhard A, Madsen L et al (2022) Dietary selenomethionine reduce mercury tissue levels and modulate Methylmercury induced proteomic and transcriptomic alterations in hippocampi of adolescent BALB/c mice. Int J Mol Sci 23:12242. https://doi.org/10.3390/ijms232012242

Naidu R, Biswas B, Willett IR, Cribb J, Singh BK, Nathanail CP et al (2021) Chemical pollution: a growing peril and potential catastrophic risk to humanity. Environ Int 156:106616. https://doi.org/10.1016/j.envint.2021.106616

Neiffer DL, Stamper MA (2009) Fish sedation, anesthesia, analgesia, and euthanasia:considerations, methods, and types of drugs. ILAR J 50:343–360

Nofal MI, Zaki V, Ahmed N, Abed-Aziz A, Rashad M (2019) Effects of heavy metal pollution on nile tilapia in Manzala farm: oxidative stress biomarkers and histopathological findings. Int J Fish Aquat Stud 7:315–328

Nomura R, Takasugi N, Hiraoka H, Iijima Y, Iwawaki T, Kumagai Y et al (2022) Alterations in UPR signaling by Methylmercury trigger neuronal cell death in the mouse brain. Int J Mol Sci 23:15412. https://doi.org/10.3390/ijms232315412

Noumedem JA, Mihasan M, Lacmata ST, Stefan M, Kuiate JR, Kuete V (2013) Antibacterial activities of the methanol extracts of ten Cameroonian vegetables against Gram-negative multidrug-resistant bacteria. BMC Complement Altern Med 13:1–9. https://doi.org/10.1186/1472-6882-13-26

NRC (2011) Nutrient requirements of fish and shrimp. National Academies, Washington, DC

Ohkawa H, Ohishi N, Yagi K (1979) Assay for lipid peroxides in animal tissues by thiobarbituric acid reaction. Anal Biochem 95:351–358. https://doi.org/10.1016/0003-2697(79)90738-3

Paglia DE, Valentine WN (1967) Studies on the quantitative and qualitative characterization of erythrocyte glutathione peroxidase. J Lab Clin Med 70:158–169. https://doi.org/10.1016/j.chemosphere.2021.130588

Papagiannis I, Kagalou J, Petridis I, Kalfakakou V (2004) Copper and zinc in four freshwater fish species from lake Pamvotis (Greece). Envir Inter 30:357–362. https://doi.org/10.1016/j.envint.2003.08.002

Peiretti PG, Meineri G, Gai F, Longato E, Amarowicz R (2017) Antioxidative activities and phenolic compounds of pumpkin (*Cucurbita pepo*) seeds and Amaranth (*Amaranthus caudatus*) grain extracts. Nat Prod Res 31:2178–2182. https://doi.org/10.1080/14786419.2017.1278597

Prasad AS, Bao B (2019) Molecular mechanisms of zinc as a pro-antioxidant mediator: clinical therapeutic implications. Antioxidants 8:164. https://doi.org/10.3390/antiox8060164

Qu L, Huang H, Xia F, Liu Y, Dahlgren RA, Zhang M et al (2018) Risk analysis of heavy metal concentration in surface waters across the rural-urban interface of the Wen-Rui Tang River, China. Environ Pollut 237:639–649. https://doi.org/10.1016/j.envpol.2018.02.020

Rana SVS (2020) Endoplasmic reticulum stress induced by toxic elements-a review of recent developments. Biol Trace Elem Res 196(1):10–19. https://doi.org/10.1007/s12011-019-01903-3

Rani S, Gupta R, Rani M (2015) Heavy metal induced toxicity in fish with special reference to zinc and cadmium. Int J Fish Aquat Stud 3:118–123

Ratnam N, Naijibullah M, Ibrahim M (2017) A review on *Cucurbita Pepo*. Int J Pharm Phytochem Res 9:1190–1194. https://doi.org/10.25258/phyto.v9i09.10305

Ray S, Vashishth R (2024) From water to plate: reviewing the bioaccumulation of heavy metals in fish and unraveling human health risks in the food chain. Emerg Contam 10(4):100358. https://doi.org/10.1016/j.emcon.2024.100358

Reda RM, Zaki EM, Aioub AA, Metwally A, Yassin MMM, Mahsoub AM F (2025) Behavioral, biochemical, immune, and histological responses of nile tilapia (*Oreochromis niloticus* Linnaeus, 1758) to lead, mercury, and pendimethalin exposure: individual and

combined effects. Environ Sci Eur 37:11. https://doi.org/10.1186/s12302-024-01047-9

Rupa SA, Patwary MAM, Matin MM, Ghann WE, Uddin J, Kazi M (2023) Interaction of mercury species with proteins: towards possible mechanism of mercurial toxicology. Toxicol Res 12:355–368. https://doi.org/10.1093/toxres/tfad039

Saddick S, Afifi M, Abu Zinada OA (2017) Effect of zinc nanoparticles on oxidative stress-related genes and antioxidant enzymes activity in the brain of *Oreochromis niloticus* and *Tilapia zillii*. Saudi J Biol Sci 24:1672–1678. https://doi.org/10.1016/j.sjbs.2015.10.021

Saewan SA, George SS (2020) Preparation of pumpkin pulp and Peel flour and study their impact in the biscuit industry. J Biol Agric Healthc 10:25–33

Saleem U, Shehzad A, Shah S, Raza Z, Shah MA, Bibi S, Chauhdary Z, Ahmad B (2021) Antiparkinsonian activity of *Cucurbita Pepo* seeds along with possible underlying mechanism. Metab Brain Dis 36(6):1231–1251. https://doi.org/10.1007/s11011-021-00707-6

Sánchez-Velázquez J, Peña-Herrejón GA, Aguirre-Becerra H (2024) Fish responses to alternative feeding ingredients under abiotic chronic stress. Animals 14:765. https://doi.org/10.3390/ani14050765

Sarasamma S, Audira G, Juniardi S, Sampurna BP, Liang S-T, Hao E et al (2018) Zinc chloride exposure inhibits brain acetylcholine levels, produces neurotoxic signatures, and diminishes memory and motor activities in adult zebrafish. Nt J Mol Sci 19(10):3195. https://doi.org/10.3390/ijms19103195

Şen G, Karaytuğ S (2017) Effects of lead and selenium interaction on acetylcholinesterase activity in brain and accumulation of metal in tissues of *Oreochromis niloticus* (L., 1758) NESci 2:21–32. https://doi.org/10.28978/nesciences.328857

Shaalan WM (2024) Hazardous effects of heavy metal pollution on nile tilapia in the aquatic ecosystem of the Eastern delta in Egypt. BMC Vet Res 20(1):585. https://doi.org/10.1186/s12917-024-04367-3

Shahjahan M, Taslima K, Rahman MS, Al-Emran M, Alam SI, Faggio C (2022) Effects of heavy metals on fish Physiology—A. Rev Chemosphere 300:134519. https://doi.org/10.1016/j.chemosphere.2022.134519

Singh S, Srivastava A, Allen T, Bhagat N, Singh N (2020) Identification of heavy metal toxicity–induced biomarkers and the protective tole of ascorbic acid supplementation in *Channa punctatus*. Int J Pharm Sci Res 11:1098–1109. https://doi.org/10.13040/IJPSR.0975-8232.11(3).1098-09

Singh S, Trivedi SP, Kumar M (2024) Prolonged exposure to mercuric chloride induces oxidative stress–mediated nephrotoxicity in freshwater food fish *Channa punctatus*. Environ Sci Pollut Res 31:36971–36985. https://doi.org/10.1007/s11356-024-33514-4

Song YF, Hogstrand C, Wei CC, Wu K, Pan YX, Luo Z (2017) Endoplasmic reticulum (ER) stress and cAMP/PKA pathway mediated Zn-induced hepatic lipolysis. Environ Pollut 228:256–264. https://doi.org/10.1016/j.envpol.2017.05.046

Song J, Kim Y-S, Lee DH, Lee SH, Park HJ, Lee D et al (2019) Neuroprotective effects of oleic acid in rodent models of cerebral ischaemia. Sci Rep 9(1):10732. https://doi.org/10.1038/s41598-019-47057-z

Srivastava NK, Prakash S (2019) Effect of zinc on the histopathology of gill, liver and kidney of fresh water catfish, *Clarias Batrachus* (Linn). Inter J Biol Inn 1:8–13. https://doi.org/10.46505/IJBI.2019.1102

Suvarna SK, Layton C, Bancroft JD (2018) Bancroft's theory and practice of histological techniques, 8th edn. Churchill Livingstone, Elsevier, England

Tahir D, Shariff M, Syukri F, Yusoff FM (2018) Serum cortisol level and survival rate of juvenile *Epinephelus fuscoguttatus* following exposure to different salinities. Vet World 11(3):327–331. https://doi.org/10.14202/vetworld.2018.327-331

Trinder P (1969) Determination of blood glucose using 4-amino phenazone as oxygen acceptor. J Clin Pathol 22:246

Waheed R, El Asely A, Bakery H, El-Shawarby R, Abuo-Salem M, Abdel-Aleem N et al (2020) Thermal stress accelerates mercury chloride toxicity in *Oreochromis niloticus* via up-regulation of mercury bioaccumulation and HSP70 mRNA. Expression Sci Total Environ 718:137326. https://doi.org/10.1016/j.scitotenv.2020.137326

Wang Y, Noman A, Zhang C, AL-Bukhaiti WQ, Abed SM (2024) Effect of fish-heavy metals contamination on the generation of reactive oxygen species and its implications on human health: a review. Fron Mar Sci 11:1500870. https://doi.org/10.3389/fmars.2024.1500870

Xia Y, Tsim KWK, Wang W-X (2023) How fish cells responded to zinc challenges: insights from bioimaging. Sci Total Environ 875:162538. https://doi.org/10.1016/j.scitotenv.2023.162538

Xu YC, Zheng H, Guo JC, Tan XY, Zhao T, Song YF (2023) Effects of different dietary zinc (Zn) sources on growth performance, Zn metabolism, and intestinal health of grass carp. Antioxid (Basel) 12(9):1664. https://doi.org/10.3390/antiox12091664

Yuan M, Fang Q, Lu W, Wang X, Hao T, Chong C-M et al (2025) Stress in fish: neuroendocrine and neurotransmitter responses. Fishes 10:307. https://doi.org/10.3390/fishes10070307

Zahran E, Ahmed F, Hassan Z, Ibrahim I, Khaled A, Palić D et al (2024) Toxicity evaluation, oxidative, and immune responses of mercury on nile tilapia: modulatory role of dietary *Nannochloropsis oculata*. Biol Trace Elem Res 202(4):1752–1766. https://doi.org/10.1007/s12011-023-03771-4

Zheng JL, Luo Z, Chen QL, Liu X, Liu CX, Zhao YH et al (2011) Effect of waterborne zinc exposure on metal accumulation, enzymatic activities and histology of *Synechogobius Hasta*. Ecotoxicol Environ Saf 74:1864–1873. https://doi.org/10.1016/j.ecoenv.2011.06.018

Zhu B, Wang Q, Shi X, Guo Y, Xu T, Zhou B (2016) Effect of combined exposure to lead and Decabromodiphenyl ether on neurodevelopment of zebrafish larvae. Chemosphere 144:1646–1654

Publisher's note Springer Nature remains neutral with regard to jurisdictional claims in published maps and institutional affiliations.

Springer Nature or its licensor (e.g. a society or other partner) holds exclusive rights to this article under a publishing agreement with the author(s) or other rightsholder(s); author self-archiving of the accepted manuscript version of this article is solely governed by the terms of such publishing agreement and applicable law.